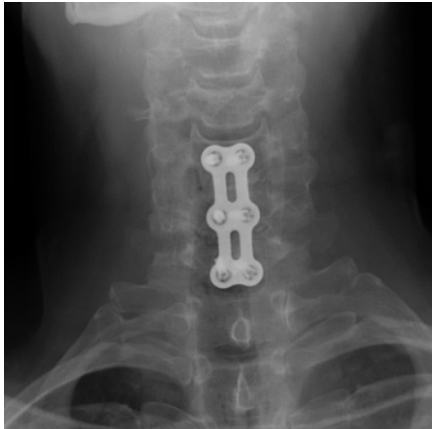


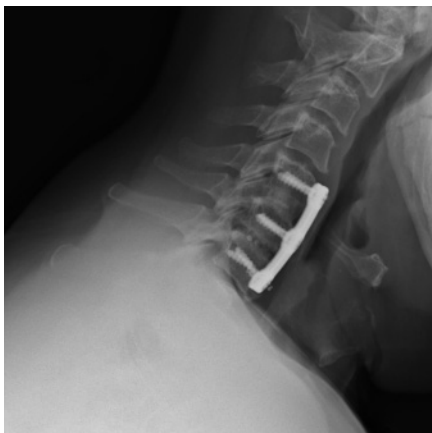
---

## ACDF Revision with UNIPLATE™ System and HEALOS® Bone Graft Replacement

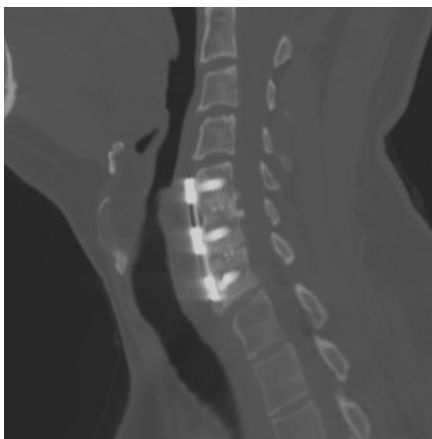
---



Pre-Op X-ray



Pre-Op X-ray



Pre-Op CT Scan

### History of Present Illness and Radiographs

A 51 year old male with a previous history of persistent radiculopathy and neurologic deficit treated with an anterior decompression of the spinal cord and anterior arthrodesis with instrumentation at C5-7 in 2004, presented for routine follow up. He was now complaining of increased neck pain and right arm paresthesias.

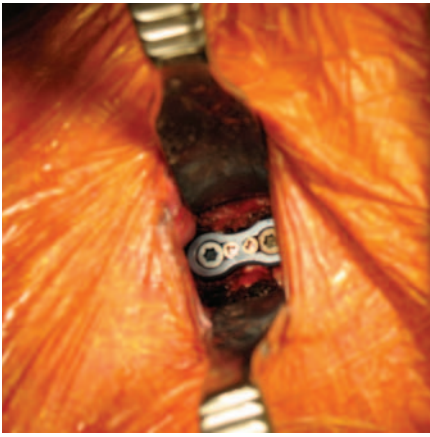
Preoperative radiographic evaluation including dynamic radiographs and thin cut CT scan, revealed a solid arthrodesis at C5-C6 and pseudoarthrosis at C6-C7 with failed hardware at C7. Specifically, the inferior left screw of C7 had broken a few millimeters from the tip and the inferior head of the right screw was also broken. Central and foraminal stenosis were also present due to hypertrophic osteophyte formation.

### Treatment Method and Materials

Due to persistent pain, the presence of a non-union and the fear of further hardware migration, the patient was counseled on operative intervention. After such counseling, the patient elected to proceed with surgical intervention and was taken to the operating room where the original plate was removed along with the failed screws at C7. Based on CT imaging, the distal tip of the left inferior screw was well within the confines of the C7 vertebral body. An attempt to surgically remove this fragment was felt unnecessary and may lead to significant destruction of the C7 vertebral body. During surgery, the C5-C7 levels were explored and found to have a solid arthrodesis at C5-C6, and a confirmed pseudoarthrosis at C6-C7.

Next, the pseudoarthrosis was taken down and revision anterior decompression of the spinal cord was performed at this level. The endplates were taken down to bleeding bone using a high-speed bur and a new structural allograft packed with HEALOS and autologous bone-marrow aspirate was impacted into position at this level.

Due to the location of the original screw holes and the retained screw fragment within the C7 vertebral body, re-instrumentation with a traditional four-hole plate could not be utilized. Therefore, a decision was made to utilize the UNIPLATE System. *(continued on back)*



*Intra-Op UNIPLATE*

Use of this plate allowed adequate fixation with a single larger midline screw per level without compromising the integrity of the vertebral bodies at the C6-7 levels.

The UNIPLATE was placed across the C6-7 level by utilizing cephalad trajectory at C6 and a slight caudal trajectory at C7 for screw placement. Both screws obtained excellent purchase during insertion.

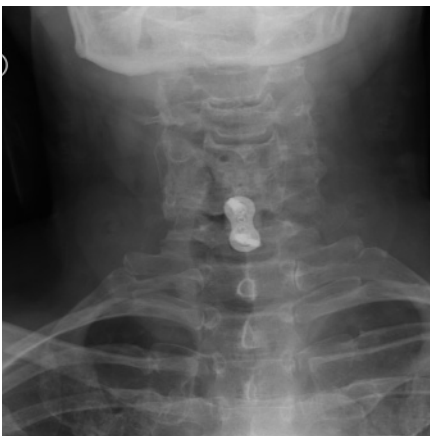Next, fluoroscopic radiographic images were obtained intra-operatively of the entire construct. The locking mechanism was then engaged and torque tightened according to protocol.

### **Follow-up Results**

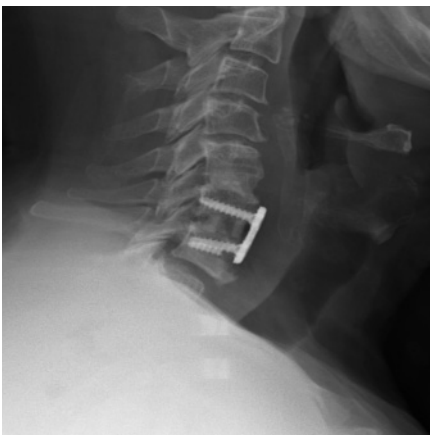
The patient tolerated the procedure well without complications. Postoperative x-ray revealed excellent position of interbody graft and excellent placement of the UNIPLATE fixation.

### **Conclusion**

This case demonstrated the successful use of the UNIPLATE system in a case where limited options were available due to the broken screw in C7. The midline screw fixation with the UNIPLATE system proved to be an optimal solution in this situation where no other reasonable anterior instrumented option existed.



*Post-Op X-ray*



*Post-Op X-ray*